**FACTA UNIVERSITATIS**
*Series*: **Medicine and Biology** Vol.15, No 2, 2008, pp. 51 - 55 UC 616.34-002.5

# ABDOMINAL LOCALISATION OF TUBERCULOSIS AND THE ROLE OF SURGERY

***Hadži-Bojan Marjanović[1], Vanja Pecić[1], Goran Marjanović[2], Vesna Marjanović[3]***

[1]*Department of Surgery, Clinical Centre Niš, Republic of Serbia*
[2]*Department of Hematology, Clinical Centre Niš, Republic of Serbia*
[3]*Clinic of Child Surgery and Orthopedics, Clinical Centre Niš, Republic of Serbia*
*E-mail: bokijaca@eunet.rs*

**Summary**. *Abdominal tuberculosis is a rare disease presented by non-specific symptoms, laboratory and radiography findings that make it difficult to diagnose. Surgical treatment of 11 patients (8 males, 3 females, age range 27-74 years), with abdominal tuberculosis was analyzed retrospectively and the literature was reviewed. Urgent surgical intervention was done in 6 cases due to peritonitis, while in 5 it was done after a minimal diagnostic procedure. Surgical exploration was done in 5 patients (45,4%), ileostomy in 4 (36,4%), right-hemicolectomy in 2 (18,2%). Six patients were operated once, 4 were operated twice and one had 4 operations. Eight patients survived (72,7%), 3 died (27,3%). Simultaneus abdominal and pulmonary involvment was registered in 6 patients (54,5%). Diagnosis of tuberculosis was confirmed with a pathology exam. Surgical intervention is very often the only diagnostic and also a therapeutic option for patients with abdominal tuberculosis.*

**Key words**: *Abdominal tuberculosis, acute abdomen.*

## Introduction

By the end of the eighties, intestinal tuberculosis was predominantly limited to endemic regions in the countries of central and South Africa, South-East Asia and India. In the USA and in western European countries it was registered sporadically in individuals who spent some time in endemic regions (1). Even more rarely, it was registered in cases with cognitive or acquired immunity disorders, such as within post transplant-therapy (2, 3). Down syndrome and in cases with progressed malignancy (4, 5). Increase in number of persons affected by tuberculosis (TB) all over the world in the last decade was registered within AIDS pandemics (6). This tendency was seen in patients with intestinal form of tuberculosis as well, followed by the most serious complications, such as ileus, fistulas, hemorrhages, tuberculosis peritonitis, often leading to death outcome.

Due to that, this form of tuberculosis can be expected to occur in our region as well.

## The Aim of the Study

Due to unspecifity of clinical picture and laboratory and radiology findings, surgery plays an important role in diagnostics and treatment of abdominal form of tuberculosis. By the number of hospitalized patients with verified TB, the authors indicate the incidence of this rare form of tuberculosis as well.

## Material and Methods

From January 2000 to March 2007, 11 patients (pts) with abdominal TB, were hospitalized and operated at the Surgery Clinic of Clinical Center in Niš. It is important to mention that 10 cases required urgent surgical intervention and due to that, preoperative diagnostics was limited to native graph of abdomen in upright position, blood count and standard laboratory analysis. Only in the case of a patient from Hematology Clinic, there was time for detailed radiographic examination with intestine passage, irigography, but for persistent anemia, aspiratory tap of bone marrow was done as well. After insight into operative finding, additional diagnostic analysis were done: Mantoux testing, seeding fresh specimen after operation on Lowenstein, as well as PH analysis of biopsy changes in abdominal organs and peritoneum, tomography of the upper part of lungs, control ultrasound examinations and CT scan.

## Results

In the period from January 2000 to March 2007, at Surgery Clinic in Niš there were 11 patients with intestinal TB. All of them were diagnosed, operated and patohistologicaly verified at the same clinic. Major clinical characteristics and the treatment outcome are showed in table 1.

Intestinal TB was more frequent in men (female: male ratio 1: 2,66). Average age was 46±15, 22. There were only 3 patients (27%) over 50 years old. In table 1

Table 1. Characteristics of patients with intestinal tuberculosis, symptomatology, treatment and outcome

| Patient | Sex | Age | Symptoms | Location | Type of Intervention | Number of interventions | Outcome |
|---|---|---|---|---|---|---|---|
| 1 | F | 32 | subocclusion | Pulmonary and ileocoecal region | Exploration | 1 | Alive |
| 2 | M | 61 | subocclusion | Pulmonary and ileocecal region | Exploration | 1 | Alive |
| 3 | M | 68 | Acute abdomen and peritonitis | Peritonitis | Exploration and lavage | 1 | Died |
| 4 | M | 27 | Ileus | Pulmonary and ileocecal region | Exploration | 2 | Alive |
| 5 | M | 42 | Acute abdomen and peritonitis | Ileocecal region | Ileostomy and closing in second act | 2 | Alive |
| 6 | M | 45 | Acute abdomen and peritonitis | Ileocoecal region | Ileostomy and closing in second act | 2 | Alive |
| 7 | F | 74 | Acute abdomen and peritonitis | Ileocoecal region<br>Intestinal perforation | Ileostomy | 1 | Died |
| 8 | M | 37 | Acute abdomen and peritonitis | Ileocoecal region<br>Intestinal perforation | Ileostomy | 1 | Died |
| 9 | F | 41 | Ileus | Pulmonary and ileocoecal region | Exploration | 1 | Alive |
| 10 | M | 45 | Acute abdomen and peritonitis | Pulmonary, stomach, duodenal ileocoecal region with stercoral peritonitis and intestinal fistulas | Right hemicolectomy with ileostemy Op2:ileotranswerso-anastomosis<br>Complications-deshicency of anastomosis Op3 ileostomy Op4. ileotranswerso anastomosis | 4 | Alive |
| 11 | M | 34 | Ileus | Pulmonary and ileocoecal region | Chemicolectomy, but on the right with ileostomy<br>Ileotranwerso anastamosis in the second act | 2 | Alive |

could be seen that 5 patients were operated only once for the purpose of exploration, lavage and biopsy of changes. The other 5 patients were operated twice. Case number 10 was operated 4 times. The same patient had a fourth intervention and after that spent 45 days at intensive care unit, with total parenteral and enteral diet support. After recovery he continued further antituberculous treatment at the Clinic for Lung diseases and Tuberculosis, Knez Selo, Clinical Center Niš, Serbia.

The data from operative reports are presented in table 2.

Presence of lesions specific for tuberculosis on histopathologic samples in operated patients made diagnosis possible, even without microbiological confirmation (Figure 1).

None of the patients had BCG vaccine scar. Visceral dissemination involving stomach was seen in 6 patients (Figure 2). Peritoneal dissemination was associated with dissemination on jejunum, duodenum and stomach as well (Table 2, Fig 3).

Table 2. Distribution of tuberculosis process in abdomen

| Localisation | Number |
|---|---|
| Stomach | 6 (54.5%) |
| Duodenum | 6 (54.5%) |
| Jejunum | 6 (54.5%) |
| Ileocecal region | 11 (100%) |
| Peritoneum | 6 (54.5%) |
| Ascites | 2 (18,2%) |
| Mesenterial lymph nodes | 11 (100%) |

From table 2 it could be clearly seen that ileocecal region was involved in all cases (Figure 4).

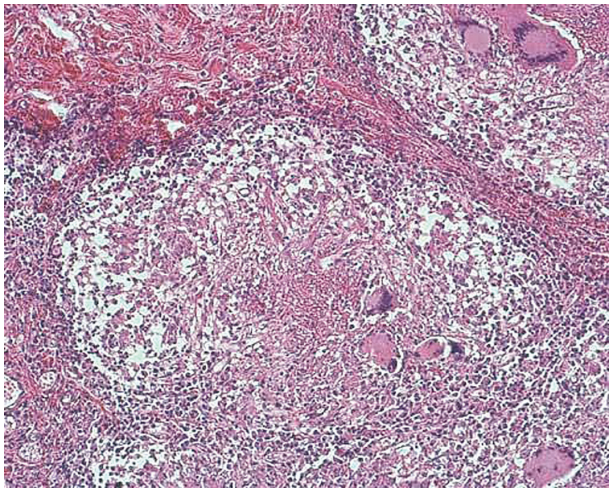

Fig. 1. Tuberculosis granuloma with epytheloid and Lang-Hans cells without central necrosis. Patient n. 5 (H&H)x20.

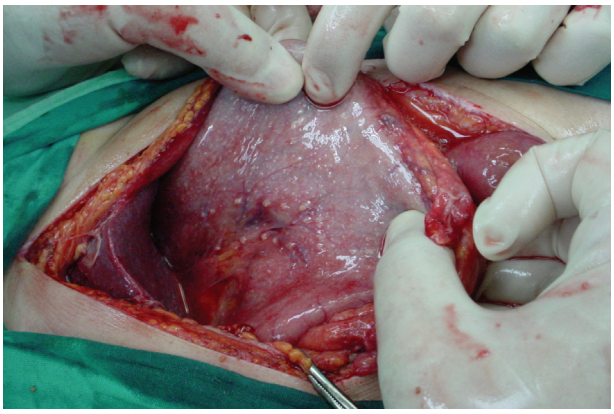

Fig. 2. Tuberculosis nodes in stomach in patient n. 10.

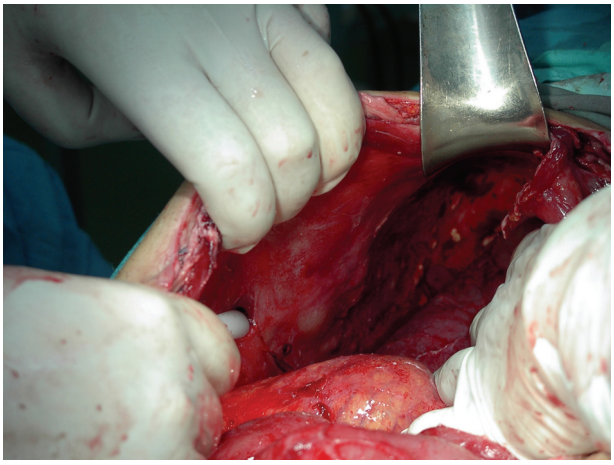

Fig. 3. Tuberculosis granulas on the inner side of abdomen cavity.

Tuberculosis peritonitis was combined with stercoral peritonitis due to perforation in ileal region in 4 patients, leading to lethal outcome in 3 cases (Figure 5, Table 1). In patients with fibro-purulent stercoral peritonitis, or with ileocecal region involvement, a temporary intestine stoma was placed. In the second or third act stoma was closed in a continent operation after 4-6 weeks. In the meantime the patients were treated with tuberculostatic therapy.

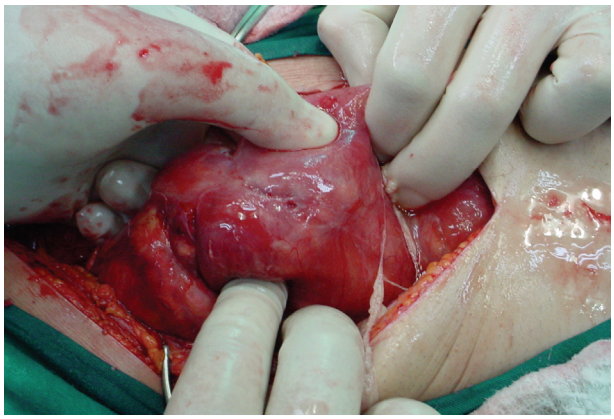

Fig. 4. Multiple adhesions on the part of ileum and perforations on the part of jejunum with fistula canal, caused perforation with difusse fibropurulent old stercoral peritonitis.

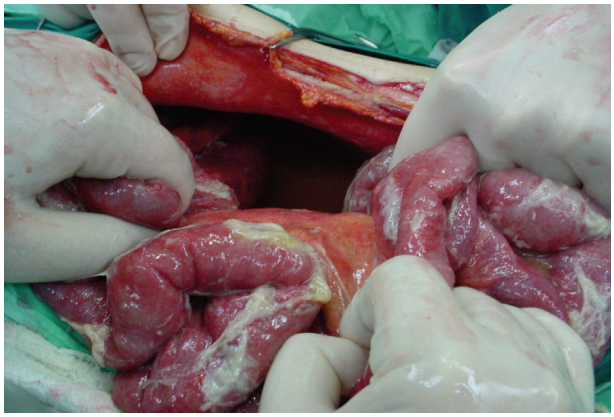

Fig. 5. Fibro-purulent layers in peritonitis


Fig. 6. Tomography of upper parts of lungs on 9 cm. Stainy shadows in both lungs upper parts and irregular unhomogenic shadow on the left side in lungs upper parts, 5cm in diameter. Patient n.2.

Presence of pulmonal tuberculosis was detected during the postoperative period, in 6 patients (54,5%), so they continued their treatment at the Clinic for Lung Diseases and Tuberculosis in Knez Selo, Niš. Figure 6 represents a tomography on 9 cm in patient n.2 with shows billateral involvement of pulmonary apex.

After surgery, all patients, continued with combined antituberculosis therapy, recommended by American and European guidelines (7). This combination consisted of Isoniazid, Rifampin, Pyrazinamide, Ethmabutol and Streptomycin.

## Discussion

Intestinal tuberculosis holds a sixth place according to involvement of extrapulmonal localizations, after lymphonodular, genitourinary, bone, miliar and meningea. There are three ways of spreading of microbacteria into abdomen: (1) hematogenically from reactivated primary foci (2 endoluminally – by ingestion of expectorated content from active pulmonary lesions, or by food ingestion, that is, milk contaminated by bacillus (presence of protective lipid capsule protects mycobacterium from enzyme and stomach acid effects, making intestine infection possible). (3) spreading infection from adjacent organs, primarily from female genital organs (8, 9).

Infection by alimentary or endoluminal way can be seen in societies where poor hygienic measures in food conservation and sanitary control of pasteurization exist.

Bacteria spreading by ingestion of expectorated bacillus and their delayed resorption by bile excretion are hypothetical and were not proved completely (9). As for localization of TB process in our patients, ileocecal region and predominantly right region of the curve, was most frequently involved. Predomination of these lesions is explained by richness of lymphoid tissue, minimal activity of digestive enzymes and maximal absorption of water and electrolytes in this area.

Although tuberculosis is the most common infection in older age, abdominal tuberculosis is more common in younger patients (10, 11). Predomination of younger patients is seen in our study too.

Clinical symptomatology is variable and unspecific with migrating pains in abdomen, weight loss, nausea, vomiting and fever. Constipation, diarrhea, nausea or ascites are possible. Chest radiography showed additional pulmonal lesions in even 54, 4% cases. Such lesions were present in up to 78% cases with abdominal tuberculosis, while sputum culture results were positive in 44% cases.(10)

Positivity of intradermal test varied from 27-94%, and only 15-20% patients showed contacomitant active pulmonal regions (12). Because of that, tuberculosis reaction has limited diagnostic value.

Radiology methods can demonstrate retroperitoneal, mesenterial, peripancreatic lymphadenopathy, as well as hepatomegally. Studies of intestinal transit with barium contrast can show rapid transit, ulcerations, stenosis or intestinal segment deformities. Non specific clinical picture, radiology, laboratory, endoscopic examinations and operative finding, can be misleading to diagnosis of ileocecal malignoma, Chron's disease or intestinal tumors like extranodal MALT (mucosa associated tissue lymphoma) (13, 14). In such cases, diagnostic dilemma can be solved only by laparoscopy or laparatomy and biopsy, as described in literature (15, 16). In most cases, like in patients from our study, definite diagnosis is made by histological analysis of biopsy material. Attempts to isolate microorganisms were laborious and unsuccessful, even in most extensive forms of intestinal tuberculosis. Diagnostic procedure has been made easier recently, thanks to commercial and more sensitive PCR tests which detect minimal quantities of mycobacterium tuberculosis in ascitic fluid, endoscopic biopsies, both fresh and paraffin (16, 17, 18).

After confirmation of tuberculosis etiology, it is recommendable to avoid surgical intervention if patient's condition is stable, because in 2/3 of cases occlusive problems stop after conservative therapy. Contrary, in cases with intestinal stenosis regions longer than 10-12 cm, or with multiple occlusive changes, surgery intervention is inevitable (19).

Incidence of laporatomy in intestinal tuberculosis patients is as high as 25-75%. After laporatomy a surgical intervenction is usually mandatory due to complications like, intestinal occlusions found in 15-60% of cases, perforation upward from stenosis site found in 1-15% of cases, abscess or fistula in present in 2-30% of cases or hemorrhage found in 2% of cases.

Finally, in cases where the intervention is inevitable, maximal reduction of manipulations with visceral organs in abdomen is recommended, to decrease spreading the infection. In the same sense, if bowel resection is inevitable, it is recommended to be strictly limited to region involved by complications, like stenosis, bleeding or bleeding site.

## Conclusion

In conclusion, abdominal tuberculosis is a disease presented by non-specific symptoms, laboratory and radiography findings that make it difficult to diagnose. Only histopathological diagnosis is correct in 100% of cases. Most patients had severe, progressed forms with developed complications, such as stenosis, hemorrhages, fistulas, perforations with peritonitis, demanding not only diagnostic, but therapeutic surgical intervention as well. A great number of death outcomes were also recorded. In minor number of cases with less extensive complications, surgical laparoscopic interventions would be a gold standard, because they make complete exploration of abdominal cavity possible, with precise biopsy of tuberculosis changes.

## References


1. Marshall JB. Tuberculosis of the gastrointestinal tract and peritoneum. Am Gastroenterol 1993; 88: 989-99.
2. Hirasaki S, Koide N, Ogawa H, Tsuji T. Active intestinal tuberculosis with esophageal candidiasis due to idiopathic CD4(+) T-lymphocytopenia in an elderly woman. J Gastroenterol 2000; 35: 47-51.
3. Ahsan N, Blanchard RL, Mai ML. Gastrointestinal tuberculosis in renal transplantation: a case report and review. Clin Transplant 1995; 9: 349-52.
4. Yoshida N, Takahashi Y, Mori M, Saitou K, Yokota S, Mathuyama S, et al. A child case of Down's syndrome with intestinal tuberculosis and tuberculous pleuritis. Kansenshogaku Zasshi 1989; 63: 1333-7. (in Japanese with English abstract)
5. Tanaka K, Kondo S, Hattori F, Yamashita Y, Matsuda M, Itoh K, et al. A case of colonic carcinoma associated with intestinal tuberculosis, and an analysis of 26 cases reported. Japan Gan No Rinsho 1987; 33: 1117-23. (in Japanese with English abstract)
6. Bargallo N, Nicolau C, Luburich P, Ayuso C, Cardenal C, Gimeno F. Intestinal tuberculosis in AIDS. Gastrointest Radiol 1992; 17: 115-8.
7. Horsburgh CR Jr, Feldman S, Ridzon R. Practice guidelines for the tretman of Tuberculosis. Clin Infec Dis 2000, 31, 633-9.
8. Horvath KD, Whelan RL. Intestinal tuberculosis: return of an old disease. Am J Gastroenterol 1998; 93: 692-6.
9. Pettengell KE, Larsen C, Garb M, Mayet FG, Simjee AE, Pirie D. Gastrointestinal tuberculosis in patients with pulmonary tuberculosis. Q J Med 1990 74: 303-8.
10. Leone V, Misuri D, Fazio C, Cardini S: La tuberculosi addominale: aspetti clinico-diagnostci e ruolo della chirurgia. Minerva Chir 2007; 62: 25-31. (in Italian)
11. Uzunkov A, Hamma M, Harma M. Diagnosis of abdominal tuberculosis: expirience from 11 cases and review of the literature. World J Gastroenterol 2004; 10: 3647-3649.
12. Collado C, Stirnemann J, Ganne N, Trichet JC, Cruaud P, Barrat C. Gastrointestinal tuberculosis: 17 cases collected in 4 hospitals in northwestern suburb of Paris. Gastroenterol Clin Biol 2005; 29: 419-24.
13. Makanjuola D. Is it Crohn's disease or intestinal tuberculosis? CT analysis. Eur J Radiol 1998; 28: 55-61.
14. Bromberg SH, Faroud S, de Castro FF, Morrone N, de Godoy AC, Franca LC. Isolated ileocecal tuberculosis simulating malignant neoplasia and Crohn's disease. Rev Assoc Med Bras 2001; 47: 125-8.
15. Gonzalez Martin MA, Diaz Oller J, Gonzalez Perez F, Esteban Urra B, Perez-Sauquillo Perez M, Enriquez Valens P, et al. Colorectal tuberculosis. Rev Esp Enferm Apar Dig 1989; 75: 712-6.
16. Akinoglu A, Bilgin I. Tuberculous enteritis and peritonitis Can J Surg 1988; 31(1): 55-8.
17. Moatter T, Mirza S, Siddiqui MS, Soomro IN. Detection of Mycobacterium tuberculosis in paraffin embedded intestinal tissue specimens by polymerase chain reaction: characterization of IS6110 element negative strains. J Pak Med Assoc 1998; 48(6): 174-8.
18. Gan H, Ouyang Q, Bu H, Li S, Chen D. Li G, et al. Value of polymerase chain reaction assay in diagnosis of intestinal tuberculosis and differentiation from Crohn's disease. Chin Med J (Engl) 1995; 108(3): 215-20.
19. Sharma MP, Bhatia V. Abdominal tuberculosis. Indian J Med Res: 2004, 120; 305-15.


# ABDOMINALNA LOKALIZACIJA TUBERKULOZE I ULOGA HIRURGIJE


***Hadži-Bojan Marjanović[1], Vanja Pecić[1], Goran Marjanović[2], Vesna Marjanović[3]***

*[1]Hirurša klinika, Klinički centar Niš*
*[2]Klinika za hematologiju, Klinički centar Niš*
*[3]Klinika za dečju hirurgiju i ortopediju, Klinički centar Niš*
*E-mail: bokijaca@eunet.rs*



Kratak sadržaj: *Abdominalna tuberkuloza je retko oboljenje koje odlikuju nespecifični simptomi koji otežavaju previlnu dijagnozu. Retrospektivno je analizirano hiruško lečenje 11 pacijenata (8 muškaraca i 3 žene, raspon godina starosti 27-74), sa abdominalnom tuberkulozom uz analizu literature. Hitna hiruška intervencija je izvršena u 6 slučajeva zbog peritonitisa, dok je kod 5 pacijenata operacija urađena nakon sprovođenja minimalnih dijagnostičkih procedura. U 5 slučajeva je urađena hiruška eksploracija (45,4%), kod 4 ileostoma (36,4%) a kod 2 je urađena desna hemikolektomija (18,2%). Šest slučajeva je operisano samo jednom, 4 je bilo operisano u dva navrata (u dva akta) dok je jedan bolesnik operisan 4 puta. Osmoro pacijenata je preživelo (72,7%), dok je troje umrlo (27,3%). Istovremena plućna I abdominalna tuberkuloza je nađena u 6 slučajeva (54,5%). U svim slučajevima, dijagnoza tuberkuloze je potvrđena patohistološki. Hiruška intervencija je veoma često jedina dijagnostička ali i terapiska mera za pacijente sa abdominalnom tuberkulozom.*



Ključne reči: *abdominalna tuberkuloza, akutni abdomen*